

# Functional and Radiological Outcome of Schatzker type V and VI Tibial Plateau Fracture Treatment with Dual Plates with Minimum 3 years follow-up: A Prospective Study

NEIL ROHRA<sup>1</sup>, HARPREET SINGH SURJ<sup>2</sup>, KEWAL GANGRADE<sup>3</sup>

## ABSTRACT

**Introduction:** High energy intra-articular fractures involving the tibial plateau causes various problems related to management like wound dehiscence, severe comminution leading to malalignment and delayed complications like varus collapse, implant failure and arthritis of knee joint.

**Aim:** This study was done to determine functional, radiological outcome and the complications of Schatzker V and VI tibial plateau fractures treated with bipillar plating with dual plates with a regular follow-up of atleast 3 years.

**Materials and Methods:** Total 34 cases of tibial plateau fracture type V and VI treated with dual plating were studied from January 2011 to December 2013 in KIMS Hospital were followed for minimum of 3 years. The patients were operated through an anterolateral approach for lateral plate and a medial column plate was put through a minimally invasive medial approach or an open posteromedial approach.

**Results:** Total 34 patients were evaluated postoperatively thoroughly for functional outcome using The Knee Society Score and radiological outcomes by Modified Rasmussen Assessment criteria which showed 29 patients (85.29%) had excellent and 5 patients (14.71%) had good objective knee society score. 24 patients (70.59%) had excellent, 8 patients (23.53%) had good and 1 patient (2.94%) were each of poor and fair functional knee society score. Eleven patients (32.35%) had excellent, 21 patients (61.76%) had good and 2 patients (5.88%) had fair radiological outcome.

**Conclusion:** We conclude that open reduction and internal fixation of high-energy tibial plateau fractures with dual plates via 2 incisions gives excellent to good functional outcome with minimal soft tissue complications. Thus, a minimally invasive approach should be used which helps in preventing soft tissue problems and helps in early wound healing. Fixation done by bipillar plating is important for early mobilization of knee joint. Early mobilization leads to better range of movements and thereby better functional outcome.

**Keywords:** Dual plating, Knee society score, Proximal tibia, Rasmussen assessment criteria

## INTRODUCTION

The knee joint is superficial joint of lower extremity and complex movements of bones takes place during the motion at knee joint [1]. Proximal tibial articular fractures can be caused by motor vehicle accidents or bumper strike injuries. Sports injuries, falls, and other less violent trauma can also frequently produce them, especially in elderly patients with osteopenia [1].

Proximal tibial plateau involvement is one of the most common intra-articular fractures. They occur as a result of either indirect trauma causing coronal fracture pattern or direct trauma causing axial compressive patterns. This comprises of 1% of all fractures [2]. The fracture patterns are very complex and may involve medial, lateral or both the tibial plateaus. All fractures have different morphology and require individualized treatment. Knowledge about type of trauma, either high energy or low energy, meniscal tears and ligament injuries helps in determining the further mode of management [2].

Tibial plateau fractures are generally classified according to the method developed by Schatzker. Schatzker type V and VI fractures are high-energy fractures often accompanied by other local and systemic injuries. Postoperative complications such as wound healing problems, infections and secondary degenerative arthritis are quite common. They tend to have a poor prognosis. High-energy tibial plateau fractures remain a challenge to orthopaedic surgeons, with the bicondylar type (Schatzker type V) and the

comminuted type (Schatzker type VI) fractures being the most difficult to treat [3].

The amount of energy involved at the time of injury determines the severity of the tibial plateau fracture. Complex fracture patterns with comminution and extensive soft tissue involvement are seen in high energy trauma. However, low energy trauma leads to simple fracture patterns and minimal soft tissue involvement. Bicondylar fractures have both tibial plateaus fractures, usually with depressed fracture of lateral tibial plateau, meniscal tears, and Anterior Cruciate Ligament (ACL) avulsions [4].

The complex comminuted fractures are associated with metaphysico-diaphyseal dissociation along with extensive soft tissue involvement [5]. Goals of treatment in such high-energy tibial plateau fractures are to maintain joint stability, congruity, and alignment without much soft tissue dissection thereby helping in early mobilization of knee joint [6]. Various modes of treatment are available for treatment of high-energy tibial plateau fractures which include definitive external fixation, dual plating, intra medullary nailing, but the best treatment method still remains controversial [2]. Different surgical approaches and various modes of fracture fixation have been developed to treat these Schatzker type V and VI fractures. These techniques of open reduction and internal fixation of individual tibial plateau helps maintain anatomic articular congruity and restoration of mechanical alignment and allows early mobilization of knee joint. Sometimes, these techniques of open

reduction and internal fixation, especially done through injured soft tissues have been associated major wound complications [2].

Various other methods of treatment have been described by various authors, each with its own merits and demerits [7]. The use of external fixators as mode of treatment often leads to joint stiffness because of delayed mobilization of knee joint [7]. Treatment by open reduction and internal fixation either with a single or dual plates through a single mid line incision causes extensive soft tissue injury of the proximal tibia, causing de-vascularization of the fracture fragments, thereby decreasing fracture healing and leading to risks of wound complications [8]. In order to improve outcome of high-energy tibial plateau fractures treatment, fixation using double buttress plates via a medial and a lateral incisions is been widely used. This technique leads to anatomic joint reduction and minimal soft tissue dissection and its associated complications and therefore adequate fixation of the fracture fragments, hence allowing early mobilization of knee joint [6].

## AIM

This study evaluated the functional and radiological outcome and complications of Schatzker V and VI tibial plateau fractures treated with a lateral plate through an anterolateral approach and a medial plate through a minimally invasive medial approach or an open posteromedial approach.

## MATERIALS AND METHODS

A prospective study was done in Department of Orthopedics in Krishna Institute of Medical Science, Secunderabad. Ethical clearance was obtained from Hospitals's Ethical Committee. Thirty four cases of tibial plateau fracture type V and VI treated with dual plating were studied from January 2011 to December 2015 and followed for minimum of 3 years. Fractures were classified according to Schatzker staging system [2]. It is classified as Type I—pure cleavage, Type II—cleavage combined with depression, Type III—pure central depression, Type IV—fractures of medial condyle, Type V—bicondylar fractures, Type VI—plateau fracture with dissociation of metaphysis and diaphysis. Selected patients were postoperatively assessed for functional outcome using the Knee Society Score [9] and radiological outcomes by Modified Rasmussen Assessment criteria [10].

Patients with pathological fractures, mental retardation and/or drug dependency, patients participating in other clinical trials of a drug or device were excluded. Severe systemic illness (active cancer, chemotherapy, uncontrolled insulin-dependent diabetes mellitus, renal failure, haemophilia, or medical contraindication for surgery), open growth plates, vascular injuries requiring repair (a Gustilo grade IIIC fracture), severe head injuries (initial Glasgow Coma Scale score <8) or other neurological conditions that would interfere with rehabilitation were also excluded. Patients who refused to participate in study or were lost to follow-up and patients less than three months post-surgery were also excluded from study.

**Management:** Injured limb was splinted with a plaster slab or knee immobilizer. The patients were operated for surgery as soon as possible depending on their medical condition, skin condition around fracture and the amount of swelling. All surgeries were done under C-arm image intensifier control.

**Operative Management:** Antero-lateral approach for the lateral plate and medial or postero-medial approach for the second plate was done. Bone grafts were used in depressed and comminuted fractures. The source of bone graft was ipsilateral iliac crest or Allograft. Prophylactic antibiotics (i.v Cefuroxime 1.5mg) were started on induction.

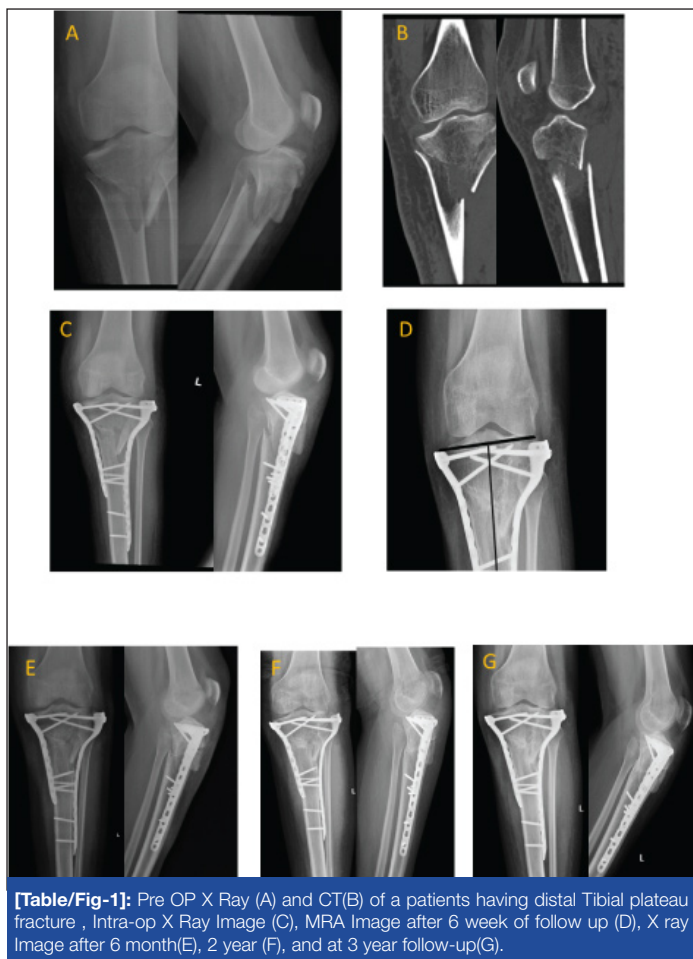**Operative procedure:** Clinical signs of soft tissue recovery included are decreased swelling, healing of fracture blisters, and wrinkling of the skin around the proximal tibia [11].

All patients were posted for surgery under regional-spinal or general anaesthesia. Patients were placed on a radiolucent table in supine position with a sand bag under ipsilateral gluteal region for the anterolateral approach. If posteromedial approach is planned, sand bag was placed on contralateral hip. All patients were operated with tourniquet inflated during surgeries.


We typically fix the medial column first. Lateral column was fixed first only if the medial condyle was severely comminuted. One-inch longitudinal skin incision was used for minimally invasive medial approach. The medial or the posteromedial fragment was exposed subperiosteally by elevating the pesanserinus with a periosteal elevator. Once the medial fragment was reduced, a small buttress plate was placed beneath the pes anserinus. Small stab incisions were used to fix the plate to the bone. Only if the fragment was posterior, open posteromedial approach was used. The saphenous nerve and vein were identified and retracted anteriorly. The posteromedial fragment was exposed by retracting pesanserinus tendons anteriorly and the medial head of the gastrocnemius laterally. Adequate visualization of fragments was done to aid in anatomical reduction. Anteromedial portion of tibia which is subcutaneous was not disturbed. Reduction of fragment was confirmed on image intensifier and fixed with a plate. We used the T buttress plate or a 3.5-mm locking proximal medial tibia plate.

Anterolateral approach for proximal tibia was done by a curvilinear longitudinal incision starting from the lateral femoral epicondyle and curving over the Gerdy's tubercle and parallel to tibial shin, just lateral to it. The iliotibial band was elevated from the Gerdy's tubercle. The tibialis anterior muscle was elevated subperiosteally to reach to lateral tibial condyle and shaft. Anatomical lateral locking plates were fixed on lateral surface and sometimes "L" buttress plate or a lateral tibial head plate was used. Tibial tuberosity avulsion fractures in seven patients were fixed with screws. When the medial plateau fracture contained a sagittal split involving the articular surface, the fracture site was entered and the coronary ligaments were elevated to expose the medial meniscus and the depressed joint surface. Test for stability were done to rule out ligamentous injury. Closure was done over suction drain. Knee was not immobilized in postoperative period. Patients were followed up to observe the postoperative rehabilitation and development of any complications. Radiographs were assessed for adequacy of articular reduction, metaphyseo-diaphyseal reduction, and alignment. If instability present or tibial tuberosity fracture was present then postoperatively hinged knee brace was given. Non weight-bearing walking and static quadriceps strengthening exercises were started on the 1<sup>st</sup> Postoperative Day (POD) itself. The rehabilitation protocol was not altered in patients with tibial tuberosity avulsion.

Mobilization was done by use of axillary crutches or a walking frame, without weight-bearing on the operated leg. Active assisted knee bending exercises and quadriceps exercises were started from 2<sup>nd</sup> postoperative day. Patients were reviewed at 2 weeks, 6 weeks, 3 month and 6 month intervals and assessment of fracture healing and knee joint range of motion till minimum of 3 years. Radiographs of the knee joint and leg were obtained in the Anteroposterior (AP) and lateral planes for assessment of the articular congruity, the metaphyseo-diaphyseal alignment or early arthritic changes [Table/Fig-1]. Patient's functional outcome was also assessed at each follow-up [Table/Fig-2]. The results were analysed according to the Oxford knee score criteria. The scores were graded as poor (<60), fair (60-69), good (70-79), and excellent (80-100). The radiological outcomes were determined by Modified Rasmussen Assessment criteria. Scores were graded as Excellent (28-30), Good (24-27), Fair (20-23), Poor (<20) [Table/Fig-3-5].



**[Table/Fig-1]:** Pre OP X Ray (A) and CT(B) of a patients having distal Tibial plateau fracture , Intra-op X Ray Image (C), MRA Image after 6 week of follow up (D), X ray Image after 6 month(E), 2 year (F), and at 3 year follow-up(G).



**[Table/Fig-2]:** Functional outcome of patient at 6 month (A), at 2 year (B) and at 3 year (C) follow-up postoperatively.

**Postoperative rehabilitation:** Static quadriceps exercises and knee mobilization was done as soon as possible as tolerated by

patient throughout the day. Partial weight bearing was started at 6-8 weeks and full weight bearing was done at 12-16 weeks. The best time for open reduction and internal fixation was within 4 hours of injury or 1 week after the injury, when swelling and the inflammatory reactions have subsided. Weight bearing is deferred until evidence of union is seen on x-rays (usual by 12-16 weeks).

**Follow-Up:** Follow-up was done at 2 weeks and then followed at 6 weeks, 3 months, 6 months and then yearly until at least 3 years. At the time of follow-up, clinical features like surgical scar, range of movements, presence of pain, instability was observed. Various radiological features like callus formation or healing, maintenance of fracture reduction, widening and depression of articular surfaces, varus and valgus collapse, signs of secondary osteoarthritis were observed.

Bony union was defined as union of at least 3 cortices in AP and Lateral views on follow-up radiographs. Nonunion was defined as absence of any signs of union at 6 months after surgery. Any articular step off of 2 mm was defined as Malreduction.

Malalignment: Alignment of the proximal tibia was determined by measuring the tibial plateau angle (the medial angle between the tangential line and anatomic axial of the tibia) on anteroposterior radiographs and the posterior slope angle (the angle between the tangential line of medial plateau and the perpendicular line of the anterior tibial cortex) on lateral radiographs; tibial plateau angle  $90^\circ$  or  $80^\circ$  or posterior slope angle  $15^\circ$  or  $-5^\circ$  was considered indicative of malalignment.

Secondary loss of reduction was defined as an increase of 2mm of intra-articular step-off, and secondary loss of alignment was defined as an increase of  $3^\circ$  malalignment when compared with the first postoperative radiograph [12].

## RESULTS

In our study, the tibial plateau fractures were most commonly due to RTA and between the age group 24 to 65 years (mean age 46.20 years). Out of 34 patients, 29(85.29%) were males and 5 (14.71%) were females. Type V were 13 (38.24%) and type VI were 21 (61.76%) and there was a slight right sided predominance (55.88%), compared to left side (44.12%). Fibula was fractured with tibia in 23 cases (67.65%). Tibial tuberosity was fractured in 7 cases (20.59%) and was fixed which helped in good knee range of motion. Blisters were present in 7 cases (20.59%) and only 4 were open case (11.76%). All associated skeletal injuries were attended and given due care appropriately. Five patients (14.71%) had ipsilateral distal femur fracture has shown knee stiffness even at end of complete follow up. Six patients (17.65%) had HTN and 9 patients (26.47%) had Diabetes. Patients were operated between 0 to 17 days on an average of 6.5 days. Nine patients (26.47%) required bone grafting, out of them 6 (17.65 %) were autograft and 3 (8.82%) were allograft. All fractures united within expected time with average time of 15.7 weeks. Not a single case of non-union was noted in our series.

Out of 34 patients, 29 patients (85.29%) had excellent and 5 patients (14.71%) had good objective knee society score.

Twenty four patients (70.59%) had excellent, 8 patients (23.53%) had good and 1 patient (2.94%) each of poor and fair functional knee society score. Eleven patients (32.35%) had excellent, 21 patients (61.76%) had good and 2 patients (5.88%) had fair radiological outcome.

Out of 34 cases, we found knee stiffness in 3 cases which continued throughout follow up. Two cases had superficial infection at 6 months, out of which one resolved by antibiotics and other re-quired debridement and then resolved. 1 case had extension lag which was not resolved through out our follow up.

Objective Knee Score	No. of Patients
Excellent (80-100)	29
Good (70-79)	5
Fair (60-69)	0
Poor (<60)	0
<b>Total</b>	<b>34</b>

[Table/Fig-3]: Objective knee score.

Functional Knee Score	No. of Patients
Excellent (80-100)	24
Good (70-79)	8
Fair (60-69)	1
Poor (<60)	1
<b>Total</b>	<b>34</b>

[Table/Fig-4]: Functional knee score.

Rasmussen Assessment criteria for Radio-logical Outcome	No. of Patients
Excellent(28-30)	11
Good(24-27)	21
Fair(20-23)	2
Poor(<20)	0
<b>Total</b>	<b>34</b>

[Table/Fig-5]: Rasmussen modified score.

## DISCUSSION

High energy intra-articular fractures involving the tibial plateau causes various problems related to management like wound dehiscence, severe comminution leading to malalignment and delayed complications like varus collapse, implant failure and arthritis of knee joint [7,12-15]. Various methods of fixation of fractures have been described like external fixation, hybrid fixator, plating through a single midline incision, plating using Mercedes Benz incision and dual plating using MIPPO techniques. It is very important to do a stable internal fixation and ligament repair in order to obtain good results of range of motion of knee joint and prevent degenerative osteoarthritis.

In our study, patients were operated between 0 to 17 days (avg=6.5 days) and 9 (26.47%) patients (6=autograft, 3 allograft) required bone grafting with an average time for union at 15.7 weeks. Various other authors like Zhang et al., showed an average of 14.1 weeks in the double buttress plate group and 13.7 weeks in the combination plate group [12]. Prasad et al., found that union occurred in 8-22 weeks (average 14 weeks) [7].

In our series, out of 34 patients, 29 patients (85.29%) had excellent and 5 patients (14.71%) had good objective knee society score. Twenty four patients (70.59%) had excellent, 8 patients (23.53%) had good and 1 patient (2.94%) each of poor and fair functional knee society score. Eleven patients (32.35%) had excellent, 21 patients (61.76%) had good and 2 patients (5.88%) had fair radiological outcome. Yu et al., Prasad et al., Zhang et al., Oh et al., Barei et al., and Barei et al., all did different studies and concluded that double plate fixation technique in high-energy Schatzker V and VI tibial plateau fractures via a 2-incision technique is a feasible treatment option for bicondylar and complex tibial plateau fractures and is matching our findings [6,7,12,13,15,16].

One case had superficial infection at 6 weeks which resolved with antibiotics. Two cases had superficial infection at 6 months, out of which 1 resolved by antibiotics and other required debridement and then resolved can be due to scratching or itching or non-absorbable suture material. One case had extension lag which was not resolved throughout our follow-up due to poor patient compliance in doing physiotherapy.

Out of 34 patients, 5 patients had redepression and varus collapse at end of our follow up due to poor patient compliance and early weight bearing by patient. There was not a single case of vascular injury as well as compartment syndrome in the entire series. Yu et al., showed knee stiffness in 9 cases, 3 cases of varus deformity, 2 cases of valgus deformity, 2 cases of wound infection (for which debridement of wound followed by external fixation were performed after implants removal), 10 cases of post-traumatic osteoarthritis of knee (for which 2 patients were operated for total knee arthroplasty at a duration of 1 year and 2 years postoperatively, and remaining 8 were followed up regularly without any need for operative procedure during the follow up periods) and 1 case of delayed union [6]. Oh et al., concluded by showing the complications like 1 cm shortening in 1 case and mild malalignments in 2 cases (varus of less than 10°). One case of superficial infection healed after removal of the plate. No cases of deep infections were seen [13]. Barei et al., showed deep wound infections in 7 cases (8.4%), out of which 3 were associated with septic arthritis (3.6%). Clinical resolution occurred only after an average of at least 3 additional procedures. In a patient with dysvascular limb requiring urgent vascular reconstruction was associated with a deep wound infection (p =0.006). Thirteen patients who required secondary procedure for complication include implant removal secondary to local discomfort, 5 patients requiring knee manipulation, 2 patients operated for excision of heterotopic ossification in order to improve knee motion, 1 patient operated for an equinus contracture release, and 1 patient operated for a metadiaphyseal nonunion. There were 16 patients (19.3%) with deep venous thromboses. No patient developed pulmonary embolism [16].

In our study, we found that there was significant improvement in objective knee society score over the follow-up with (p<0.0001). Also, there was significant difference in radiological outcome between 6 weeks and 6 months with redepression and varus collapse in 5 cases with p=0.032. But our follow up duration was only of 3 years and long term follow up of at least 6-8 years is required for diagnosis of secondary osteoarthritis [7,17-20].

At end of follow up, study shows that there was significant difference in objective, functional knee society score and radiological outcome. Even if there is good radiological outcome but still patients are having excellent functional outcome with p<0.0001.

Treatment strategy is guided by initial evaluation of fracture pattern, which was done using routine AP, lateral and CT scan images with 3D reconstruction done in all the patients. The posteromedial fragments are usually not distinctly outlined on routine X-rays, and are usually visualized on the lateral views. Most of the classification systems (Schatzker and AO) are based on the anteroposterior X-ray appearances [21,22]. Bhattacharyya et al., stressed the importance of evaluating tibial plateau fractures on lateral views, criticizing the above fact [23]. The peculiar fracture patterns are explained by the typical anatomical considerations. The medial part of the knee is concave to the tibial side and the femoral condyle glides fairly confined in the tibial cavity. There is a blasting effect on tibia during the axial loading of femur. As the tibial plateau is posteriorly directed, resultant force vector is directed posteriorly, thus leading to a posterior split. Hence it is imperative to bear in mind the possibility of a posteromedial fracture fragment [24].

With the use of image intensifier in order to aid in indirect reduction techniques and by the use of k wires as joysticks, reduction of the articular and metaphyseal fragments were obtained without much soft tissue damage. Moreover with use of minimally invasive techniques for plate insertion and screw insertion on the medial side, soft tissue complications could be prevented. Rigid fixation of proximal tibia by use of lateral and medial plates helped in knee

mobilization in the immediately in postoperative period. Also, tibial tuberosity avulsion was fixed with screws for allowing early knee mobilization [7]. Prasad et al., also used 2 thick k-wires and tension band wire which helped in maintaining reduction and start early mobilization. This ability to start early aggressive knee rehabilitation has helped us achieve excellent functional outcome, as functional outcome of knee surgeries is so directly related to knee range of motion in our patient population.

Loss of articular reduction of <2 mm was observed in three patients and loss of 2-4 mm in 1 patient which was mainly due to screw loosening in the osteoporotic bone in metaphyseal region, but there was no effect in functional recovery. This may be due to presence of articular cartilage whereby minor articular cartilage incongruity was easily tolerated [18,25,26]. We used techniques like fluoroscopy and submeniscal arthrotomy in order to visualize the articular reduction. Methods available are fluoroscopy, arthrotomy and arthroscopy [27-29]. Associated injuries, fracture union, objective knee society score and radiological outcome have an effect on functional outcome. Associated injuries if present have good functional outcome, whereas if absent have excellent functional outcome. Earlier the fracture union, excellent is the result, whereas slight delay in fracture union will have good result. Better the objective knee score, excellent is the result. Better the MRA radiological score, excellent is the result.

Age, fracture union, objective and functional knee society score outcome have an effect on final radiological outcome. Lesser the age of patient, better is the radiological outcome.

Earlier the fracture union, excellent is the result, whereas slight delay in fracture union will have good result. Better the MRA radiological score, better the objective knee score. Better the MRA radiological score, better the Functional knee score. Hence, appropriate handling of the soft tissues using non-traumatic methods and a staged surgery helps in soft tissue healing and decreased complications following definitive fixation. Locking plates are said to provide angular stability, which we could hypothesize using locking plates instead of buttress plates which would help prevent secondary loss of reduction and maintain alignment. Raza et al., also concluded in their study that use of precontoured locking plates and locking screws have improved the outcome of treatment [30].

Anatomic reduction of the proximal tibial articular surfaces and appropriate alignment of the limb axis with stable internal fixation allows early joint motion, which is the final goal of the treatment. In cases of bicondylar tibial plateau fractures, only lateral plating leads to varus deformity which can be prevented by bipillar plating through dual incisions [7,12,13,16]. Anterolateral and posteromedial skin incisions allow a wide skin bridge between the two incisions and decrease the chances of skin necrosis and infections and without compromising the vascularity of underlying bone. Anterolateral approach allows elevation of the depressed lateral plateau and bone graft if required to be placed under the elevated fragment and fixation with proximal tibial locking plate. This fixed angle construct provides angular stability and prevents collapse of the elevated fragment. The posteromedial or posterior approach provides buttressing of the medial plateau and application of posterior or posteromedial plates. This combined approach allows the reduction and fixation of entire tibial plateau. Thus in cases of this typical fracture pattern we recommend fixation of the medial plateau with posterior or posteromedial plates.

## CONCLUSION

We conclude that for high energy tibial plateau fractures open reduction and internal fixation with dual plates using 2 incisions leads to excellent to good functional outcome without much soft tissue complications. This minimally invasive approach should be used wherever possible, which helps prevent soft tissue

complications, and thus early wound healing. Good fixation done by dual plating is necessary to start early rehabilitation. Obtaining full range of movements depends mainly on early knee range of motion, and provides optimal functional recovery and good outcome.

The overall postoperative functional and radiological outcomes indicate that MIPPO technique is a good treatment option for bicondylar tibial plateau fractures. Our outcomes are consistent with the international standards. Although the technique is technically demanding, the bipolar plate fixation helps in providing reliable stability without any additional adjuvant external fixation in post op period. The postoperative complications can be reduced by proper timing of surgery, good extraperiosteal dissection and avoiding dissection of comminuted bone fragments.

## REFERENCES

- Canale Terry S, Beaty James H. Campbell's Operative Orthopaedics: Fractures of lower extremity: Tibial plateau. 11<sup>th</sup> ed. Philadelphia: Mosby Elsevier; 2007; Vol(3): p2094- 2111.
- Watson JJ and Wiss AD. Rockwood and Green's fractures in adults: Fractures of the proximal tibia and fibula. Bucholz RW and Heckman JD Ed. 5<sup>th</sup> ed. Philadelphia: Lip-pincott Williams and Wilkins; 2001; 2: 1799-1839.
- Ali AM, Yang L, Hashmi M, Saleh M. Bicondylar tibial plateau fractures managed with the Sheffield Hybrid Fixator. Biomechanical study and operative technique. *Injury*. 2001;32(4):SD86-91.
- Berkson EM, Virkus WW. High-energy tibial plateau fractures. *J Am Acad Orthop Surg*. 2006;14(1):20-31.
- Papagelopoulos PJ, Partinevelos A, Themistocleous GS, Mavrogenis AF, Korres DS, Soucacos PN. Complications after tibia plateau fracture surgery. *Injury*. 2006;37(6):475-84.
- Yu Z, Zheng L, Zhang Y, Li J, Ma B. Functional and radiological evaluations of high energy tibial plateau fractures treated with double-buttress plate fixation. *Eur J Med Res*. 2009;14(5):200-05.
- Prasad GT, Kumar TS, Kumar RK, Murthy GK, Sundaram N. Functional outcome of Schatzker type V and VI tibial plateau fractures treated with dual plates. *Indian J Orthop*. 2013;47(2):188-94.
- Chin TYP, Bardana D, Bailey M, Williamson OD, Miller R, Edwards ER, et al. Functional outcome of tibial plateau fractures treated with the fine-wire fixator. *Injury*. 2005;36(12):1467-75.
- Scuderi GR, Bourne RB, Noble PC, Benjamin JB, Lonner JH, Scott WN. The new Knee Society Knee Scoring System. *Clin Orthop Relat Res*. 2012;470(1):3-19.
- Rasmussen DS. Tibial condylar fractures, Impairment of knee joint stability as an indication of surgical treatment. *J Bone Joint Surg Am*. 1973;55(7):1331-50.
- Tscherne H, Lobenhoffer P. Tibial plateau fractures, management and expected results. *Clin Orthop Relat Res*. 1993;(292):87-100.
- Zhang Y, Fan D, Ma B, Sun S. Treatment of complicated tibial plateau fractures with dual plating via a 2-incision technique. *Orthopedics*. 2012;35(3):e359-64.
- Oh CW, Oh JK, Kyung HS, Jeon IH, Park BC, Min WK, et al. Double plating of unstable proximal tibial fractures using minimally invasive percutaneous osteosynthesis technique. *Acta Orthop*. 2006;77(3):524-30.
- Hassankhani EG, Kashani FO, Hassankhani GG. Treatment of complex proximal tibial fractures (types v & vi of schatzker classification) by double plate fixation with single anterior incision. *Open journal of Ortho*. 2013;3:208-12.
- Bareil DP, Nork SE, Mills WJ, Henley MB, Benirschke SK. Complications associated with internal fixation of high-energy bicondylar tibial plateau fractures utilizing a two-incision technique. *J Orthop Trauma*. 2004;18(10):649-57.
- Bareil DP, Nork SE, Mills WJ, Coles CP, Henley MB, Benirschke SK. Functional outcomes of severe bicondylar tibial plateau fractures treated with dual incision and medial and lateral plates. *J Bone Joint Surg Am*. 2006;88(8):1713-21.
- Wang SQ, Gao YS, Wang JQ, Zhang CQ, Mei J, Rao ZT. Surgical approach for high-energy posterior tibial plateau fractures. *Indian J Orthop*. 2011;45(2):125-31.
- Buckwalter JA, Brown TD. Joint injury, repair, and remodeling: roles in posttraumatic osteoarthritis. *Clin Orthop Relat Res*. 2004;(423):7-16.
- Volpin G, Dowd GS, Stein H, Bentley G. Degenerative arthritis after intraarticular fractures of the knee, long term results. *J Bone Joint Surg Br*. 1990;72(4):634-38.
- McKinley TO, Rudert MJ, Koos DC, Brown TD. Incongruity versus instability in the etiology of posttraumatic arthritis. *Clin Orthop Relat Res*. 2004;(423):44-51.
- Schatzker J, McBroom R, Bruce D. The tibial plateau fracture, the Toronto experience: 1968-1975. *Clin Orthop Relat Res*. 1979;(138):94-104.
- Müller ME, Allgöwer M, Schneider R, et al. Manual der osteosynthese [M]. Berlin: Springer Verlag. 1982: 142-43.
- Bhattacharyya T, McCarty LP, Harris MB, Morrison SM, Wixted JJ, Vrahas MS. The posterior shearing tibial plateau fracture: treatment and results via a posterior approach. *J Orthop Trauma*. 2005;19(5):305-10.
- Eggli S, Hartel MJ, Kohl S, Haupt U, Exadaktylos AK, Roder C. Unstable bicondylar tibial plateau fractures: a clinical investigation. *J Orthop Trauma*. 2008;22(10):673-79.
- Kraus TM, Freude T, Stöckle U, Stuby FM. Pearls and pitfalls for the treatment of tibial head fractures. *Orthopade*. 2016;45(1):24-31.

- [26] Honkonen SE. Degenerative arthritis after tibial plateau fractures. *J Orthop Trauma*. 1995;9(4):273-77.
- [27] Watson JT. High energy fractures of the tibial plateau. *Orthop Clin North Am*. 1994;25(4):723-52.
- [28] Young MJ, Barrack RL. Complications of internal fixation of tibial plateau fractures. *Or-thop Rev*. 1994;23(2):149-54.
- [29] Buchko GM, Johnson DH. Arthroscopy assisted operative management of tibial plateau-fractures. *Clin Orthop Relat Res*. 1996;(332):29-36.
- [30] Raza H, Hashmi, P Abbas K, Hafeez K. Minimally invasive plate osteosynthesis for tibial plateau fractures. *J Orthopaedic Surgery*. 2012;20(1):42-47.

**PARTICULARS OF CONTRIBUTORS:**

1. Orthopedic Surgeon, Department of Orthopedics, Vinoba Bhave Civil Hospital, Gujarat, India.
2. Department of Orthopedics, JJ Hospital, Mumbai, India.
3. Department of Orthopedics, Government Medical College, Indore, India.

**NAME, ADDRESS, E-MAIL ID OF THE CORRESPONDING AUTHOR:**

Dr. Neil Rohra,  
Orthopedic Surgeon, Department of Orthopedics, Vinoba Bhave Civil Hospital, Gujarat-388325, India.  
E-mail: drneilrohra@gmail.com

Date of Submission: **Jan 07, 2016**Date of Peer Review: **Jan 27, 2016**Date of Acceptance: **Mar 02, 2016**Date of Publishing: **May 01, 2016****FINANCIAL OR OTHER COMPETING INTERESTS:** None.